

Evolution of Midface Rejuvenation

Robert J. DeFatta, MD, PhD; Edwin F. Williams III, MD

Age is the most significant factor contributing to the overall change in the appearance of an individual's facial features over time. This gradual process of structural weakening of the face begins during the third decade and continues to worsen during the remainder of an individual's lifetime. In this article we discuss how the approach to midface rejuvenation has evolved over time owing to our increased understanding of the aging process. In addition, we discuss specific techniques that we employ that have helped us achieve more natural and lasting results.

Arch Facial Plast Surg. 2009;11(1):6-12

One of the earliest changes to occur in the aging process is the descent of the eyebrows, creating the appearance of smaller eyes. This is followed by the appearance of excess skin laxity, pseudoherniation of orbital fat through a weakened septum resulting from laxity in the orbicularis retaining ligaments in both the upper and lower eyelids with the additional laxity of the zygomaticocutaneous ligaments in the lower eyelids, descent of the malar fat pad, and the formation of glabellar frown lines, and an increased prominence of the nasolabial folds during the fourth decade (**Figure 1**). The fifth decade brings deepening of the forehead wrinkles, glabellar furrows, and crow's feet. At the same time, in the lower face, jowling begins to occur along the mandibular line, and vertical lines begin to form in the perioral region (**Figure 2**). In the sixth decade, prominent wrinkling occurs in the perioral region and the neck, the nose begins to droop, and the lateral canthus weakens, causing a downward slant of the lateral eyes. Also, the glabellar and forehead wrinkles continue to deepen and become evident even at rest. One of the most prominent occurrences in the aging pro-

cess is the descent of the midface structures, which results in a worsening appearance of the nasojugal folds and lower eyelids. The seventh decade brings a thinning of the skin and fat resorption throughout the face. Finally, during the eighth decade, all of the changes that have already occurred become exaggerated while the skin continues to thin because of a diminishing subcutaneous fat distribution (**Figure 3**).¹

The purpose of the midface-lift procedure is to reverse the aging process that has occurred in an individual. This can be accomplished through various techniques that have been developed to date. However, whichever procedure is used, the ultimate goal is the same, that is, to reposition and augment the facial tissues in such a way as to return a more youthful and rested appearance to an individual's face in lieu of introducing an "operated appearance" during the process.

HISTORICAL PERSPECTIVE

Prior to World War I, physicians were often guarded in sharing their wisdom regarding cosmetic surgery procedures owing to the lack of acceptance. In fact, the American medical establishment of the 1920s called for a ban on cosmetic surgery.²

The first case of surgical treatment of rhytids occurred in 1912 by Hollander.³

Author Affiliations: Department of Facial Plastic and Reconstructive Surgery, Williams Center, Plastic Surgery Specialists, Latham, New York, and Departments of Facial Plastic and Reconstructive Surgery and Surgery, Division of Otolaryngology–Head and Neck Surgery, Albany Medical Center, Albany, New York.

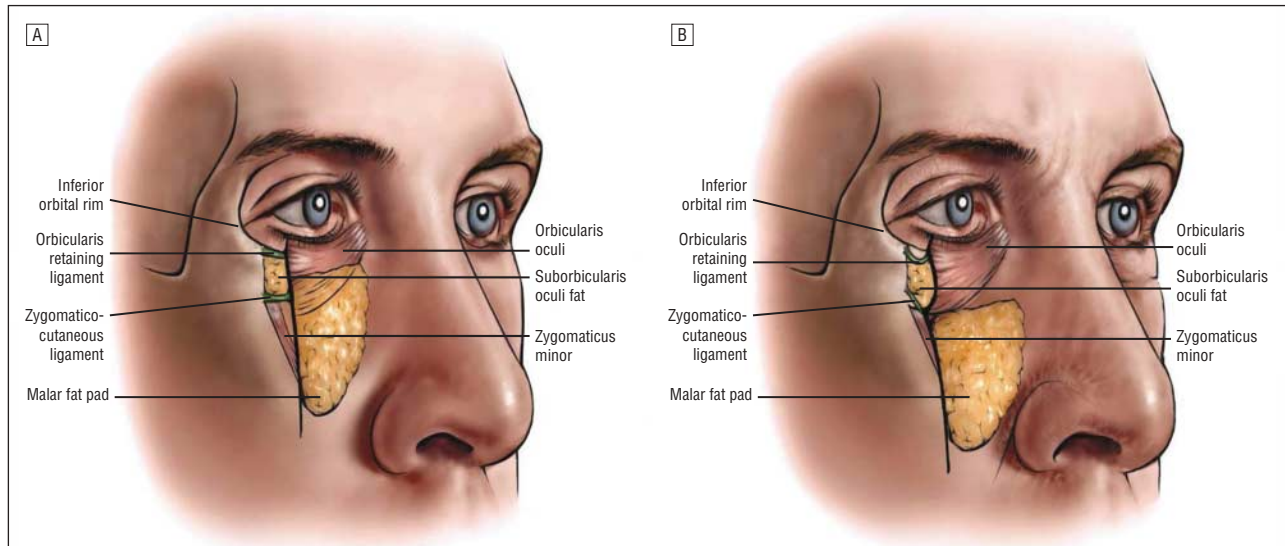


Figure 1. Aging process in the lower eyelids and midface. A, An example of a youthful eyelid and midface in which the orbital septum of the lower eyelid is still taut and there is no laxity in either the orbicularis retaining ligaments or the zygomaticocutaneous ligaments. B, With age, orbital fat begins to pseudoherniate through a weakened septum owing to laxity in the orbicularis retaining ligaments and the additional laxity of the zygomaticocutaneous ligaments. In addition, the malar fat pad begins to descend.



Figure 2. Aging process in the fifth decade.

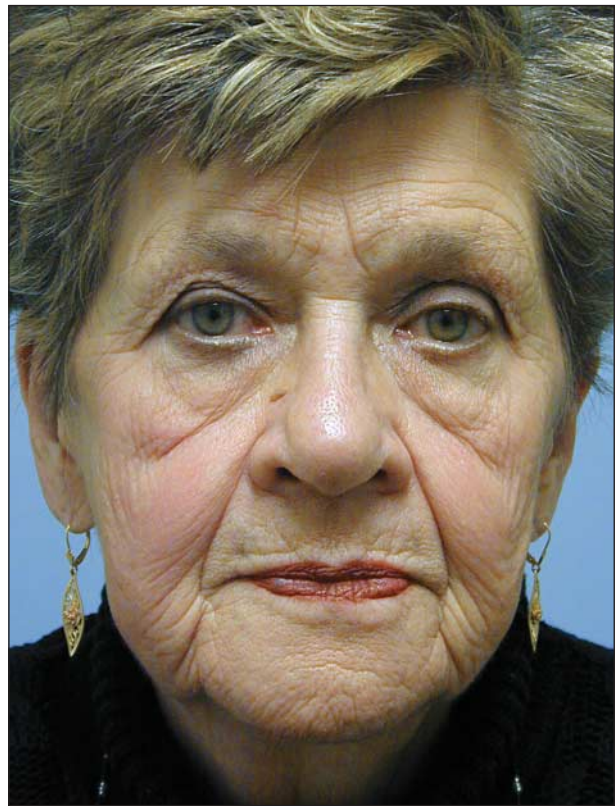


Figure 3. Aging process in the eighth decade.

Shrouded in secrecy, distinguished European physicians such as Lexer,⁴ Passot,⁵ Joseph,⁶ and Noel⁷ continued to refine facial rejuvenation techniques. During this time, Miller⁸ is credited as publishing the first article furthering the development and refinement of the midface-lift in the United States.

These first techniques consisted of interrupted incisions placed both in front of and behind the ears in natural creases and were combined with limited strips of ex-

cised skin. In 1920 and 1921, Bettman⁹ and Bourguet¹⁰ were independently credited with the first subcutaneous rhytidectomy. Unlike previous procedures, this one consisted of extensive undermining and lipectomy. The next important contribution occurred in 1928 when the posttragal incision was introduced by Joseph.⁶

More recently, technique modifications have occurred to address the dissatisfaction with the lack of long-term correction that occurred with the "classic" skin un-

dermining from the procedures described in the early 1900s. In 1960, Aufricht attempted to prolong the longevity of the lift by advocating suturing deep to the superficial fat. This was followed by the Skoog¹¹ technique in 1974, in which the fascia and platysma muscle were undermined to the level of the melolabial fold and jowl in an attempt to address the lower third of the face. In 1976, the discovery of the superficial musculoaponeurotic system (SMAS) by Mitz and Peyronie¹² confirmed the existence of a fascial layer investing the facial mimetic musculature. This layer was noted to lie in a tissue plane that is continuous with the platysma below and the temporoparietal fascia above and is anatomically distinct from the underlying parotidomasseteric fascia. It is also important to note that this was the first approach that advocated the effectiveness of imbrication as a rhytidectomy technique.

In the 1990s, the emphasis turned to improving the midface, traditionally the most difficult region of the face to effectively address. This was accomplished through the introduction of the deep plane and composite rhytidectomy, which was pioneered by Hamra.¹³ He realized that by undermining the orbicularis oculi muscle through a lower blepharoplasty approach and joining this with the face-lift dissection, he could create a composite flap that was composed of the orbicularis oculi, cheek fat, and platysma muscle. Repositioning the composite flap corrected these 3 ptotic areas while maintaining their relationship with each other and the skin.¹³ Disadvantages of this approach are that by completely disassociating the orbicularis oculi muscle and the underlying lateral canthus, eyelid malposition and ectropion can occur. This can be very troublesome to the patient, as well as being difficult to correct. In addition, this approach left patients with prolonged edema, which makes this approach less appealing to some patients. With this in mind, even the experienced surgeon should realize that there is a steep learning curve involved in obtaining the high standard of results that Hamra¹³ describes before attempting this procedure.

The importance of the advances introduced by Hamra¹³ is exemplified by their incorporation into newer, theoretically less invasive techniques. Ramirez¹⁴ was one of the pioneers in developing the endoscopic approach to the midface. He noted that the midface dissection had several components, which required careful elevation of the suborbicularis oculi fat pad with the underlying periosteum along the inferior orbital rim and malar areas. By starting his dissection in the temporal area and creating a tunnel between the malar-zygomatic arch and the temporal pocket, he was able to suspend the midface suborbicularis oculi fat pad to the temporal fascia. He also noted that a Caldwell-Luc incision facilitates more expedient dissection of the midface. In a further understanding of how the lower eyelid and cheek act as 1 unit, Ramirez¹⁴ observed that upward lifting of the midface facilitates removal of considerable amounts of skin from the lower eyelid. In fact, he noted that at least twice as much skin on the lower eyelid can be removed when this procedure is used compared with standard approaches. He¹⁴ also felt that during blepharoplasty, the pretarsal orbicularis oculi muscle should be preserved to prevent com-

plications such as ectropion.¹⁵ This approach has been the preferred midfacial rejuvenation approach of the senior author (E.F.W.) since 1995, excluding the intralateral approach.

In 2000, Hester et al¹⁵ published a report of their technique to address the midface using a transconjunctival blepharoplasty approach. This dissection was connected with a subperiosteal cheek-lift. This technique was designed to correct midfacial aging by a central, direct approach while avoiding an extensive peripheral to central dissection in the subcutaneous, the sub-SMAS, or in the deep plane. Although this approach addressed the cheek-eyelid complex as one, the approach still required a canthopexy owing to the disruption of the lateral canthus.¹⁵

The most recent advancement in midface rejuvenation has been brought about through a clearer understanding of how the aging process leads to hand-in-hand changes occurring in the lower eyelid complex and the midface, which are 2 of the most common causes of a patient's initial consultation for facial rejuvenation. Although the various youth-restoring midface-lift, eyebrow-lift, lower face rhytidectomy, and blepharoplasty procedures reposition the skin, the subcutaneous tissues, and fat pads to reverse the aging process, they fail to effectively improve the original volume loss with natural and long-lasting results. Therefore, this problem was the initial impetus for a more direct, safe approach to address this area of the face.

This concept was first addressed in 1992 by Terino¹⁶ when he published his concept of facial rejuvenation using alloplastic facial contouring. He felt that by using techniques based on the concepts of zonal anatomy, the facial skeleton could be augmented with a minimum of complications. The alloplastic onlays considerably improved facial contour by correcting both hereditary deficiencies in youth as well as aging changes. The concept of volumetric enhancement using alloplastic implants was expanded when Flowers¹⁷ described the correction of the tear trough deformity through this technique.

Owing to the widespread acceptance of alloplastic augmentation in the periorbital and midface regions, Coleman¹⁸ introduced what he felt was a reliable method of soft-tissue augmentation to correct periorbital changes associated with aging in 1994. He published his philosophy and technique of soft-tissue augmentation and lifting with fat grafting in the periorbital region and postulated the need for supporting and filling instead of excising and suspending.¹⁸

RELEVANT ANATOMY

A youthful eyelid consists of a slight upward slope from the medial to lateral canthi, along with an almond-shaped horizontal palpebral fissure. With the patient in forward gaze, the lower eyelid should be positioned 1 to 2 mm above the lower edge of the limbus (nonprominent eye) or slightly below the limbus (prominent eye). The lower eyelid should have good tone and be free of tarsal ligament laxity, canthal tendon laxity, pseudoherniation of fat, or skin excess. In the youthful patient, the distance from the upper edge of the lower eyelid to the

eyelid/cheek junction should be no more than 8 to 12 mm. In addition, this transition should be smooth and positioned at the infraorbital rim.

During the aging process, rounding of the palpebral fissure occurs along with laxity of the lateral canthal tendon. It is the lateral canthal tendon laxity that leads to a loss of the upward slant of the lateral canthus, resulting in a tired appearance of the eyes. The combination of these defects, along with laxity of the tarsal ligament, results in an elongation of the vertical aperture of the eye and eventual scleral show.

A combination of laxity in both the muscle and skin contributes to decreased eyelid tone, which allows for visual irregularities in the lower eyelid secondary to pseudoherniation of fat through the orbital septum owing to laxity in the orbicularis retaining ligaments in both the upper and lower eyelids with the additional laxity of the zygomaticocutaneous ligaments in the lower eyelids. The increased laxity ultimately results in a descent of the eyelid/cheek junction and increased vertical length of the lower eyelid, the combination of which allows for the visualization of the infraorbital rim through the lower eyelid skin. Therefore, the youthful shorter and fuller lower eyelid is slowly replaced by a longer and volume-deflated eyelid whose junction with the midface is displaced inferiorly. At this time, the malar fat pads descend, resulting in a loss in the cheek prominence, a tear trough eyelid deformity, and the appearance of prominent nasolabial folds (**Figure 4**).

In the early 20th century, the senior author (E.F.W.) critically analyzed his results following midface rejuvenation through the subperiosteal, transtemporal lifting procedure up to that point and noted that his less-than-ideal outcomes occurred in patients who had experienced severe volume loss. These shortcomings were found to be particularly evident in the “T zone,” which anatomically encompasses the lower eyelids and the malar eminence, down the nasolabial folds to the mesiolabial lines, and the perioral area. As previously stated, volume loss results from a combination of atrophy of the subcutaneous fat and muscle, as well as loss of the underlying skeletal framework. Over the previous 5 years, combining volume restoration through lipotransfer with lifting procedures has been instrumental in elevating these procedures to a new level of excellence in a comprehensive approach to facial rejuvenation.

We have found that these changes in the eyelid/cheek complex can effectively be addressed during midface rejuvenation by augmenting this region with volume in addition to the traditional approaches that are used to address the midface. It has become very evident that, despite effective repositioning of the ptotic soft tissues of the midface, facial rejuvenation may remain incomplete because of the persistent loss of volume that has occurred in these patients (**Figure 5**). By augmenting our midface-lift procedure with lipotransfer, we have been able to improve our aesthetic results in a reliable and lasting fashion. We specifically transfer fat in patients undergoing a midface-lift because these are the 4 key areas where volume loss is most prominent. These include the tear trough/infraorbital rim, the malar eminence, the submalar region, and the nasolabial crease. Additional areas

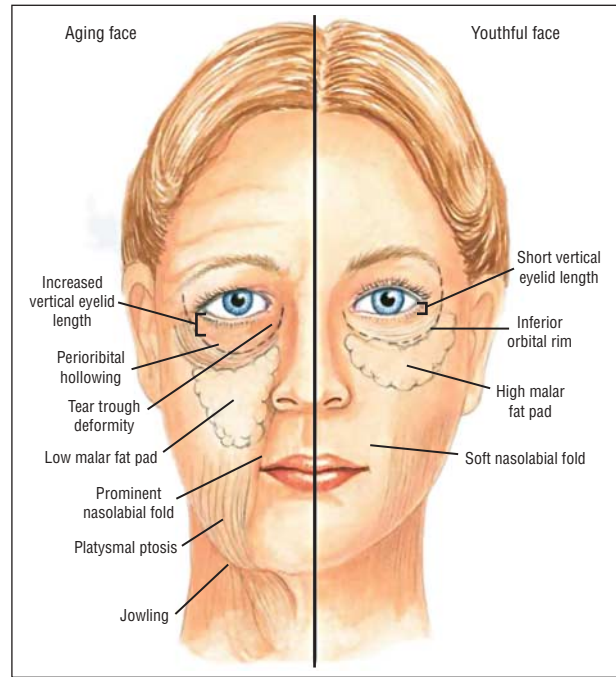


Figure 4. Youthful face vs aging face. Note how the increased laxity in the orbicularis retaining ligaments and the zygomaticocutaneous ligaments ultimately results in a descent of the lid-cheek junction and increased vertical length of the lower eyelid. Also, the malar fat pads descend, resulting in a loss in the cheek prominence, a tear trough eyelid deformity, and the appearance of prominent nasolabial folds.

where volume loss is present in some patients include the temporal fossa, the jawline, the glabella, the lateral eyebrow, and the perioral region.

Although we still seek the one perfect procedure that can address all of the complex factors that occur in the midface during the aging process, lipotransfer has been very instrumental in helping us to better address the aging process that occurs in the eyelid/cheek complex. Fat embodies several ideals for soft-tissue volume restoration of the face: it is inexpensive, readily available, and easily harvested; it is biocompatible and pliable; and fat does not rely on tissue reaction to provide volume enhancement. The earliest report of lipotransfer was by Neuber¹⁹ in 1893; he used autologous fat to repair depressed scars. Since then, several authors have reported on the use of autologous fat as a soft-tissue filler for progressive hemifacial atrophy, congenital anomalies (hemifacial microsomia, cleft lip and palate, Treacher Collins–Franceschetti syndrome), and acquired defects (rhytids, folds, facial scars, and atrophy from facial paralysis).²⁰⁻²³ However, it was not until the mid 1990s that lipotransfer was considered for aesthetic purposes when Coleman²⁴ described a technique of 3-dimensional liposculpture using “tissue parcels” of fat and not as individual cells. He reasoned that small parcels of fat have the best chance of developing a blood supply and surviving.²⁴

The overwhelming concern with lipotransfer is longevity. Coleman²⁴⁻²⁶ has shown in progressive reports that this technique of liposculpture has longevity and has presented up to 6.5 years of follow-up data showing no resorption of fat, whereas others^{27,28} have observed 3- to 5-year long-term survival of fat. Several histologic studies^{29,30} support the rationale of transplanting small quan-

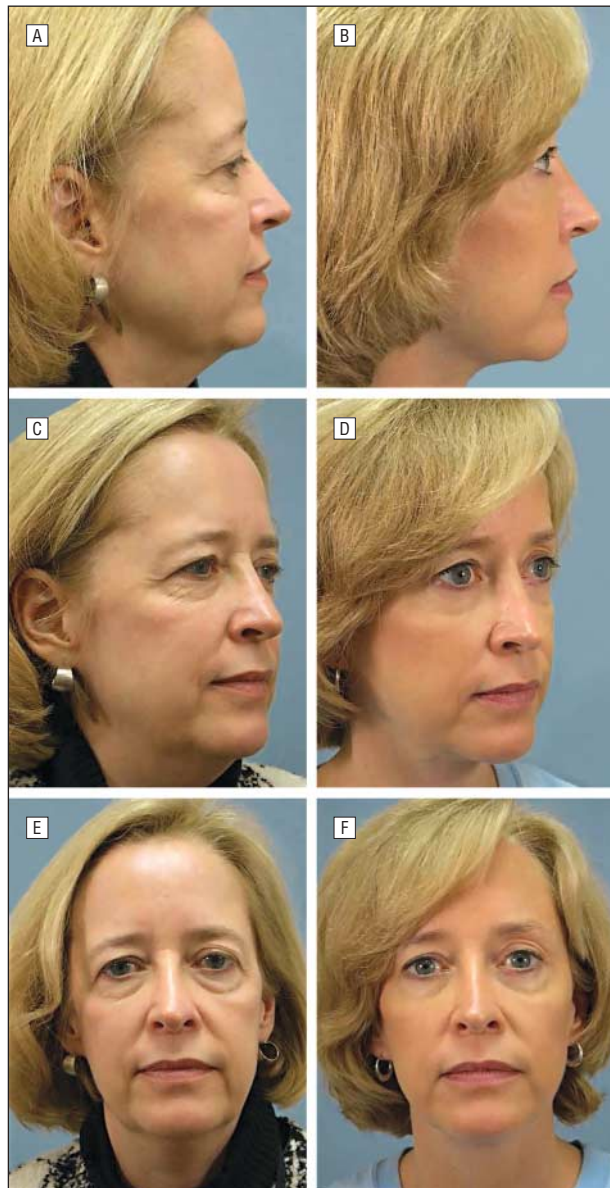


Figure 5. Midface rejuvenation without volume restoration. This is an example of a patient at 1 year after surgery in which the midface and lower face were addressed through standard techniques. Note that although the patient had effective repositioning of the ptotic soft tissues of the midface, she still experienced a loss of volume in the lower eyelids and the midface. Preoperative (A) and postoperative (B) lateral views. Preoperative (C) and postoperative (D) oblique views. Preoperative (E) and postoperative (F) front views.

tities of fat in contact with well-vascularized tissue. A pivotal study by Guerrerosantos et al³¹ demonstrated that muscle thickness continued to increase for 6 months after fat grafting had occurred within the muscle, whereas Pinski and Roenigk³² reported that fat surviving at 6 months will continue to endure.

As lipotransfer techniques have continued to evolve, Amar³³ described the fat autograft muscle injection technique, which involves injection of fat within the muscles of facial expression. He found that the delivery of fat into muscle ensures close proximity to an excellent blood supply and addresses the volume loss associated with muscle and fat atrophy.³³

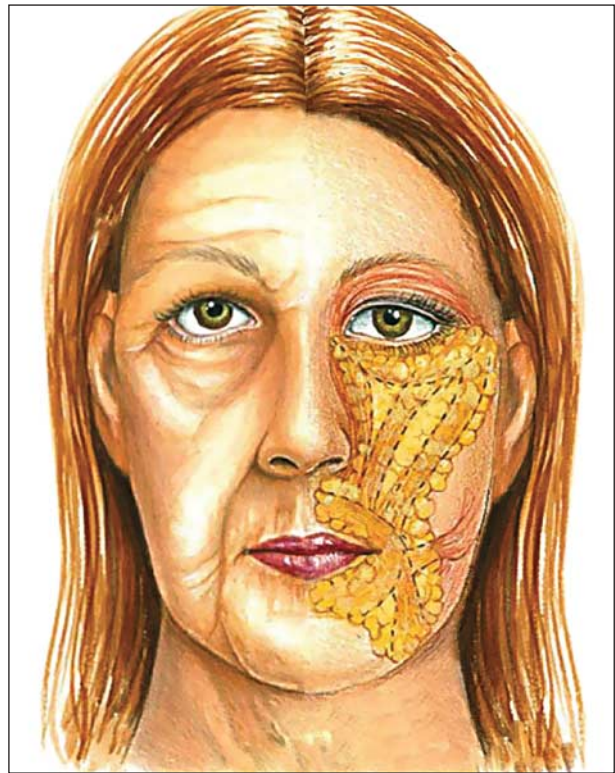


Figure 6. Lipotransfer to the midface. To restore volume, fat is transferred to the lower eyelids, the distribution of the zygomaticus major and minor muscles, the nasolabial folds, and the marionette lines.

SURGICAL TECHNIQUE

When considering the midface, certain key structures must be addressed to allow for a thorough release of the overlying tissues that will result in a lasting result. First, the osteocutaneous ligament of the midface must be addressed. It is located over the body of the zygoma. This ligament is firm and anchors the skin to the zygoma in a vigorous fashion. There is little chance of elevating the midface without releasing this ligament. Also notable is the location of the transfacial artery through this ligament.³⁴

The periosteum of the zygoma and maxilla is connected to the fascia of the masseter. This thick tissue must be dissected and elevated from the muscle to generate movement of the midfacial soft tissue.³⁵ It is quite important to generate the movement necessary for a noticeable difference in the outcome.

The periosteum of the zygoma and inferior orbital rim is thick and relatively easy to elevate.³⁶ In fact, the ease of dissection can lead to injury to the infraorbital nerve. In concert with the periosteum of the inferior orbital rim is the arcus marginalis. This structure is more of a lower eyelid structure, but it represents a definable separator of the lower eyelid and the midface. It is formed by the septum orbitale of the lower eyelid and the thin muscle fascia of the deep aspect of the orbicularis oculi muscle. Release of this structure can aid in blunting the junction between the lower eyelid and the midface.

We approach the midface through an endoscopic approach, which has been previously described.^{37,38} If we feel that the patient is experiencing a volume deficiency following the repositioning of the ptotic tissues, we will

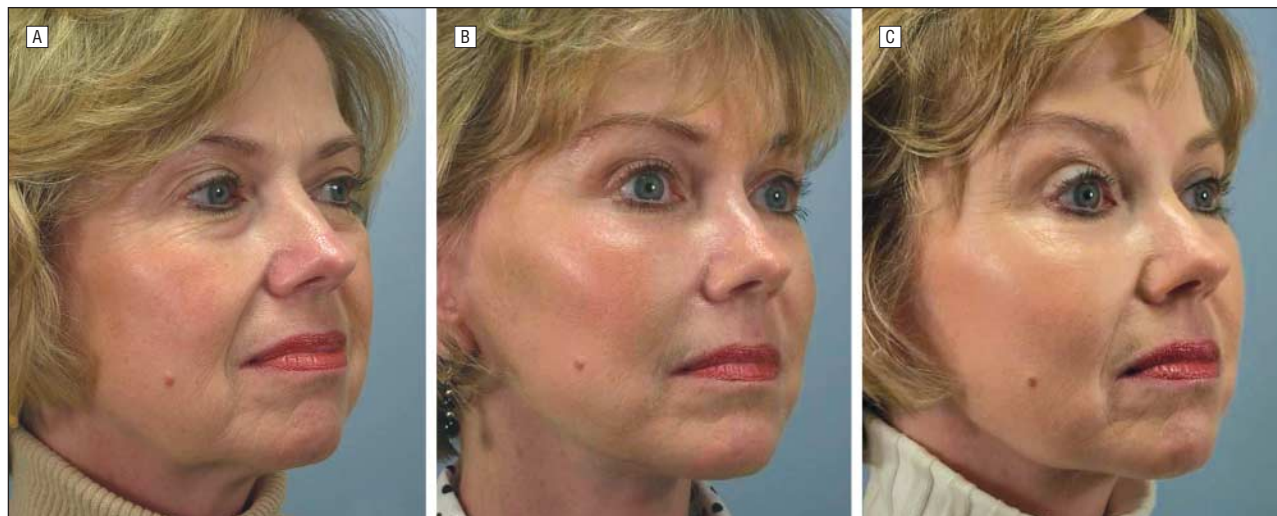

Figure 7. Surgical results following midface rejuvenation procedure and lipotransfer. A, The patient before her surgical intervention. B, One year after her midface-lift, which was augmented with lipotransfer. Note how the added volume of the lipotransfer helps to restore the youthful appearance. C, The patient at 2-year follow-up. Note that there has been some volume loss, but most of the volume was still present at this time, helping to restore the patient's youthful appearance.

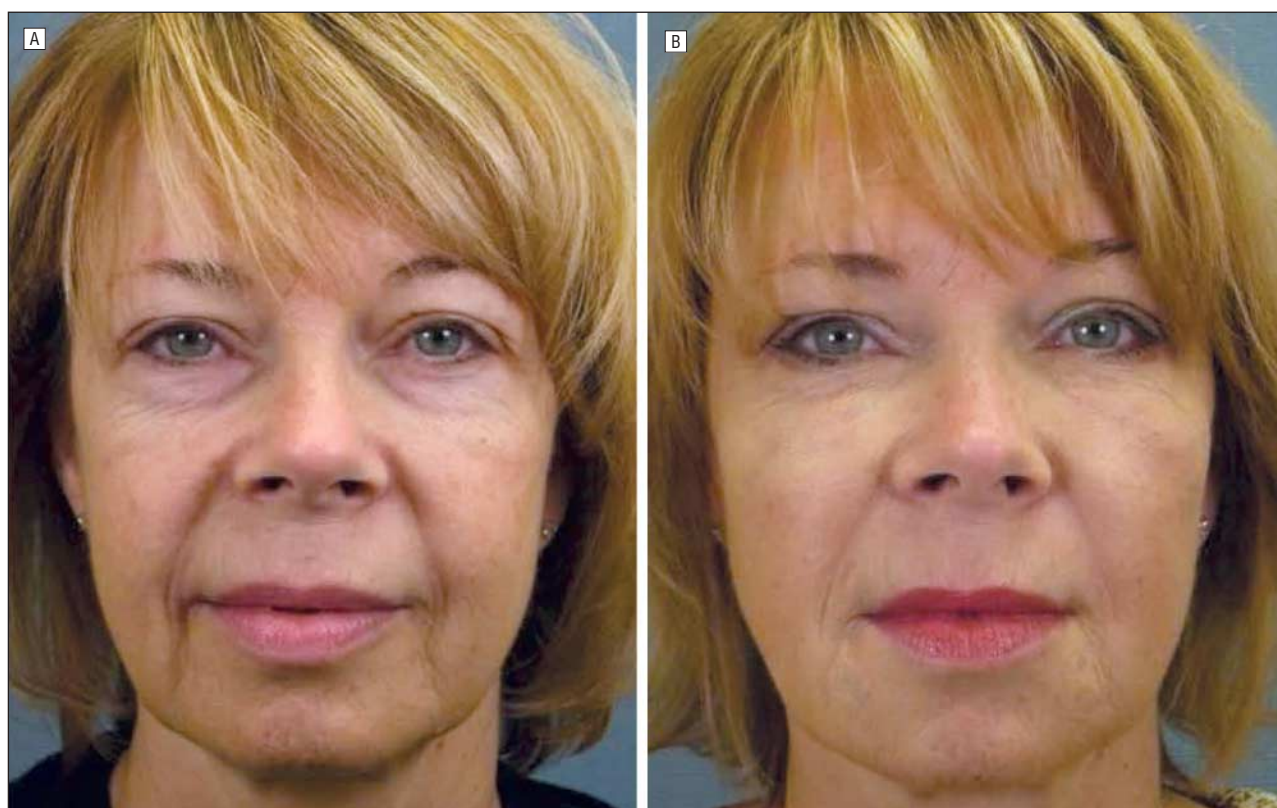

Figure 8. Volume restoration through treatment with Radiesse (BioForm Medical Inc, San Mateo, California). A, The patient before volume restoration. B, Four months after injection of 4 mL of Radiesse to the lower eyelids, the nasolabial folds, and marionette lines.

then augment these areas with fat (**Figure 6**). This procedure is used as an adjunct to most of our traditional midface-lift procedures because the aging process in these key areas is not only the result of ptosis of tissues but also the result of a loss of volume resulting from a combination of atrophy of subcutaneous fat and muscle, as well as a loss of skeletal framework (**Figure 7**).

It should be noted that another alternative to restoring volume in this area is through fillers, such as Re-

stylane (Medicis Aesthetics Inc, Scottsdale, Arizona) and Radiesse (BioForm Medical Inc, San Mateo, California). In addition, because these fillers have a finite lifetime, we feel that the patient will ultimately incur a higher financial responsibility while experiencing the inconvenience of undergoing sequential procedures for the preservation of the volume enhancement that was accomplished in 1 sitting with lipotransfer. Ultimately, we believe that restoration of facial volume can be safely, precisely,

and reliably achieved by lipotransfer, which can be tailored to an individual's areas of variable aging to achieve a more customized outcome (**Figure 8**).

To date, we have been performing lipotransfer as an adjunct to our endoscopic midface rejuvenation for 5 years. Analyzing our results, we feel that most patients maintain 70% to 80% of their fat transfer over a 2-year period. One of the variables that we have encountered is the loss of volume after the 2-year period. Although it is hard to determine which patients are good candidates, we have found that there are certain patients who are more prone to volume loss, including those who are in the midst of a very stressful event in their life, those at the extremes of age, and patients who have a very low body mass index to begin with and exercise strenuously on a daily basis.

One of the main challenges in evaluating the longevity of lipotransfer is the reliable volumetric assessment from 2-dimensional photographs. However, with software that can perform volumetric analysis becoming more mainstream, this should be less of a problem, as long as all variables are held constant from one set of photographs to another.

CONCLUSIONS

Midface rejuvenation is an evolving field in which 1 specific procedure cannot address all of the individual needs of patients. In our practice, the evolution of the midface-lift routinely includes the addition of fat transfer to the operation. In fact, over the past 5 years, we have performed over 300 operations in which fat was transferred to rejuvenate individual locations in the midface, including 250 lipotransfers to the lower eyelid complex and 242 to the midface. One of the main reasons why we use lipotransfer so frequently is that we have found that many patients who undergo a midface-lift have a substantial tear trough deformity and infraorbital skeletonization (either from previous blepharoplasty or aging) that can be emphasized with a midface-lift alone. By combining fat transfer to the tear trough/infraorbital rim with the midface-lift, we are able to create a youthful convex contour between the lower eyelid and the cheek, which provides superior aesthetic results and long-term correction. In addition, the nasolabial crease can be improved with fat transfer.

Accepted for Publication: August 28, 2008.

Correspondence: Edwin F. Williams III, MD, Department of Facial Plastic and Reconstructive Surgery, Williams Center, Plastic Surgery Specialists, 1072 Troy Schemnectady Rd, Latham, NY 12110 (edwilliamsmd@pol.net).

Author Contributions: *Study concept and design:* DeFatta and Williams. *Drafting of the manuscript:* DeFatta and Williams. *Statistical analysis:* DeFatta and Williams.

Financial Disclosure: None reported.

REFERENCES

1. Friedman O. Changes associated with the aging face. *Facial Plast Surg Clin North Am.* 2005;13(3):371-380.
2. Fomon S. *The Surgery of Injury and Plastic Repair.* Baltimore, MD: Williams & Wilkins; 1939.
3. Hollander E. Cosmetic surgery. In: Joseph M, ed. *Handbuch der Kosmetik.* Leipzig, Germany: Verlag von Velt; 1912:688.
4. Lexer E. *Die gesamte Wiederherstellungschirurgie.* Vol 2. Leipzig, Germany: J. A. Barth; 1931:548.
5. Passot R. *La Chirurgie esthetique pure: Techniques et Results.* Paris, France: Gaston Doin et Cie; 1931:176-180.
6. Joseph J. *Nasenplastik und sonstige Gesichtsplastik nebst einem Anhan uber Mamaplastik.* Leipzig, Germany: Verlag von Curt Kabitzsch; 1928-1931.
7. Noel A. La chirurgie esthetique. In: *Son Role Social.* Paris, France: Mason et Cie; 1926:62-66.
8. Miller CC. *The Correction of Featural Imperfections.* Chicago, IL: Oak Printing; 1907.
9. Bettman A. Plastic and cosmetic surgery of the face. *Northwest Med J.* 1920;19:205.
10. Bourguet J. La chirurgie esthetique de la face. *Concours Med.* 1921:1657-1670.
11. Skoog T. *Plastic Surgery: New Methods and Refinements.* Philadelphia, PA: W. B. Saunders; 1974.
12. Mitz V, Peyronie M. The superficial musculoaponeurotic system (SMAS) in the parotid and cheek area. *Plast Reconstr Surg.* 1976;58(1):80-88.
13. Hamra ST. Composite rhytidectomy. *Plast Reconstr Surg.* 1992;90(1):1-13.
14. Ramirez OM. Endoscopic full facelift. *Aesthetic Plast Surg.* 1994;18(4):363-371.
15. Hester TR, Codner MA, McCord CD, et al. Evolution of technique of the direct transblepharoplasty approach for the correction of lower lid and midfacial aging: maximizing results and minimizing complications in a 5-year experience. *Plast Reconstr Surg.* 2000;105(1):393-406.
16. Terino EO. Alloplastic facial contouring: surgery of the fourth plane. *Aesthetic Plast Surg.* 1992;16(3):195-212.
17. Flowers RS. Tear trough implants for correction of tear trough deformity. *Clin Plast Surg.* 1993;20(2):403-415.
18. Coleman SR. The technique of periorbital lipoinfiltration. *Oper Tech Plast Reconstr Surg.* 1994;1:120.
19. Neuber F. Fettransplantation: Bericht uber die Verhandlungen der Dt Ges f Chir. *Zentralbl Chir.* 1893;22:66.
20. Moscona R, Ullman Y, Har-Shai Y, et al. Free fat injections for the correction of hemifacial atrophy. *Plast Reconstr Surg.* 1989;84(3):501-507.
21. Chajchir A, Benzaquen I. Liposuction fat grafts in face wrinkles and hemifacial atrophy. *Aesthetic Plast Surg.* 1986;10(2):115-117.
22. Illouz YG. The fat cell graft: a new technique to fill depressions. *Plast Reconstr Surg.* 1986;78(1):122-123.
23. Teimourian B. Repair of soft-tissue contour deficit by means of semiliquid fat graft. *Plast Reconstr Surg.* 1986;78(1):123-124.
24. Coleman SR. Long term survival of fat transplants: controlled demonstrations. *Aesthetic Plast Surg.* 1995;19(5):421-425.
25. Coleman SR. Facial recontouring with liposculpture. *Clin Plast Surg.* 1997;24(2):347-367.
26. Coleman SR. Structural fat grafts: the ideal filler? *Clin Plast Surg.* 2001;28(1):111-119.
27. Guerrero Santos J. Long term outcome of autologous fat transplantation in aesthetic facial contouring. *Clin Plast Surg.* 2000;27(4):515-542.
28. Kaminer MS, Omuar NE. Autologous fat transplantation. *Arch Dermatol.* 2001;137(6):812-814.
29. Carpaneda CA, Ribeiro M. Study of the histologic alterations and viability of adipose tissue grafts in humans. *Aesthetic Plast Surg.* 1993;17(1):43-47.
30. Niechajev I, Sevcuk O. Longterm results of fat transplantation: clinical and histologic studies. *Plast Reconstr Surg.* 1994;94(3):496-506.
31. Guerrero Santos J, Gonzalez-Mendoza A, Masmela Y, et al. Long term survival of free fat grafts in muscle: an experimental study in rats. *Aesthetic Plast Surg.* 1996;20(5):403-408.
32. Pinski KS, Roenigk HH. Autologous fat transplantation: a long term follow-up. *J Dermatol Surg Oncol.* 1992;18(3):179-184.
33. Amar RE. Microinfiltration adipocytaire au nouveau de la fac, ou restructuration tissulaire par greffe de tissu adipeux. *Ann Chir Plast Esthet.* 1999;44(6):593-608.
34. Duffy MJ, Friedland JA. The superficial-plane rhytidectomy revisited. *Plast Reconstr Surg.* 1994;93(7):1392-1403.
35. Hobar PC, Flood J. Subperiosteal rejuvenation of the midface and periorbital area: a simplified approach. *Plast Reconstr Surg.* 1999;104(3):842-851.
36. Dempsey PD, Oneal RM, Izenberg PH. Subperiosteal brow and midface lifts. *Aesthetic Plast Surg.* 1995;19(1):59-68.
37. Pontius AT, Williams EF III. The extended minimal incision approach to midface rejuvenation. *Facial Plast Surg Clin North Am.* 2005;13(3):411-419.
38. Krishna S, Williams EF III. Lipocontouring in conjunction with the minimal incision brow and subperiosteal midface lift: the next dimension in midface rejuvenation. *Facial Plast Surg Clin North Am.* 2006;14(3):221-228.